



En ligne
<https://www.atrss.dz/ajhs>



Case report

Cellulite orbitaire de l'enfant : à propos d'un cas

Orbital cellulitis in infant: Case Report

Souad Bouayed[✉], Chouaib Bensaadi, Sofiane Ait baziz, Djamil Souttou
Algiers faculty of Medecine, Algeria

Abstract

This case report is about a 14 months old baby, who've presented a left side orbital cellulitis evolving 6 days prior her admission, after a badly managed ocular traumatism which was treated with oral nonsteroidal anti-inflammatory (NSAI). Symptoms included Swelling and redness of the eyelid, pain and proptosis. Rapidly, this infant was admitted at the hospital and underwent a CT scan, blood analyses, which showed an orbital cellulitis, classified Chandler stage II, with elevation of the reactive C protein, and leucocytes count. The infant was treated with intravenous antibiotics with a successful response within 10 days.

In summary, with this case, we would like to report an uncommon child orbital cellulitis evolving after ocular traumatism and stress out the danger of a misdiagnosis and inappropriate therapy, which could lead to severe complications.

KEYWORDS: Orbit, cellulitis, children, case report.

RESUME

Ce cas décrit un nourrisson de 14 mois qui consulte pour cellulite orbitaire de l'œil gauche évoluant depuis 06 jours à la suite d'un traumatisme orbitaire mal pris en charge et traité par des anti-inflammatoires non stéroïdiens. Devant le ptosis, les douleurs, l'œdème et la rougeur des paupières, le nourrisson a été hospitalisé et a bénéficié d'un scanner orbitaire et d'examen de laboratoire révélant une cellulite atteignant les tissus profonds de l'orbite, classée stade II de Chandler avec hyperleucocytose et élévation du taux de CRP. Rapidement, une antibiothérapie a été instaurée par voie parentérale avec de bons résultats obtenus au bout de 10 jours.

En résumé, ce cas illustre une cellulite orbitaire inhabituelle chez l'enfant survenant après un traumatisme orbitaire et met l'accent sur les risques d'une thérapeutique mal adaptée.

MOTS clés : Orbite, cellulite, enfants, cas clinique.

* Auteur Corredpondant. Tel.: +213698980732
 Adresse E-mail : soulelouche@gmail.com
 ORCID : <https://orcid.org/0000-0002-3278-1441>

Date de réception : 31/08/2022
 Date de révision : 06/11/2022
 Date d'acceptation: 14/01/2023

DOI: 10.5281/zenodo.7539177



Introduction

Orbital cellulitis is an infection of the deep orbital tissues associated with marked proptosis and ophthalmoplegia. This affection may lead to some potential lethal complications as cavernous sinus thrombosis, meningitis, brain abscess and permanent visual loss due to optic neuritis or orbital nerve ischemia[1].

The majority of infant's orbital cellulitis are due to a secondary extension of acute or chronic bacterial sinusitis, especially the ethmoid sinuses or from the other periorbital structures[2-3]. Exogenous causes, including traumatism, remain rare in children and should stress the necessity of a close monitoring of every orbital trauma in children, and avoiding auto medication that could lead to severe complications.

Observation

A 14-months-old girl without any personal or familial medical history, came to the Children's Emergency department after six days of a progressively evolving left facial swelling and proptosis starting two days after a left side orbital traumatism which was responsible of a 5mm linear wound of the upper eyelid. The temperature was 38 °C.

Two days after the onset of complaints (Swelling, redness and fever), the parents consulted a general practitioner who prescribed topical eye drops (local antibiotics) and oral nonsteroidal anti-inflammatory (NSAI) drugs. Apparently, there was no relief. In fact, the case having got worse, the child was urgently referred to us for appropriate care. Examination revealed diffuse erythematous swelling of the left upper eyelid. The opening of the eye was impossible. Congestion along with purulent discharge was present in this eye (fig.1). Clinical examination of ocular movements, pupil reactions and Fundus was therefore limited. The examination of the right eye was normal.

Blood tests showed a raised C-reactive protein and white blood cells count. The CT scan showed features of orbital cellulitis in the left eye (fig.2) classified Chandler stage II without any sinusitis.

Considering those results, the diagnosis of orbital cellulitis stage II has been established and the child was admitted. Regarding the high risk and speed of the case evolving into cavernous sinus thrombosis, treatment should be started without delay.

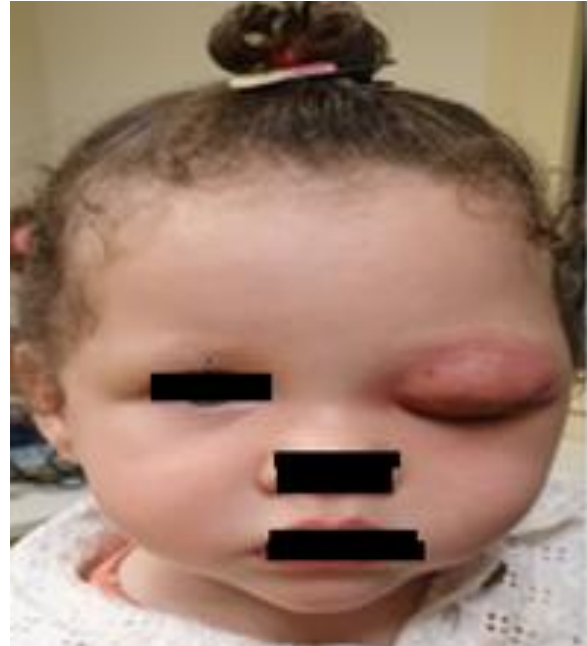

Figure 1: Clinical photography showing severe and total left eyelid ptosis (the opening of the left eye was impossible), proptosis and swelling

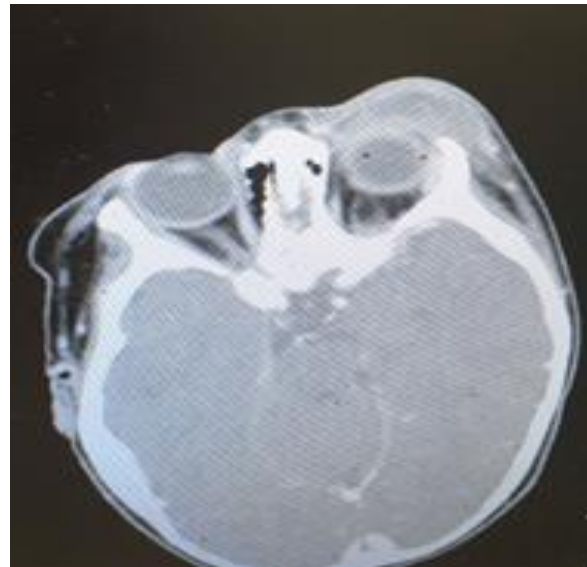


Figure 2: axial CT scan showing an orbital cellulitis Chandler stage II on the left side

The baby was managed with intravenous antibiotics including cefotaxime, amikacin and metronidazole for one week followed by oral cefotaxime for one week. For the fever, non-inflammatory steroids were stopped and replaced by intravenous paracetamol.

The clinical response was rapidly favorable after 48 hours with a marked reduction of the edema and opening of the eye (fig.3). A total recovery was obtained by the 10th day (fig.4).

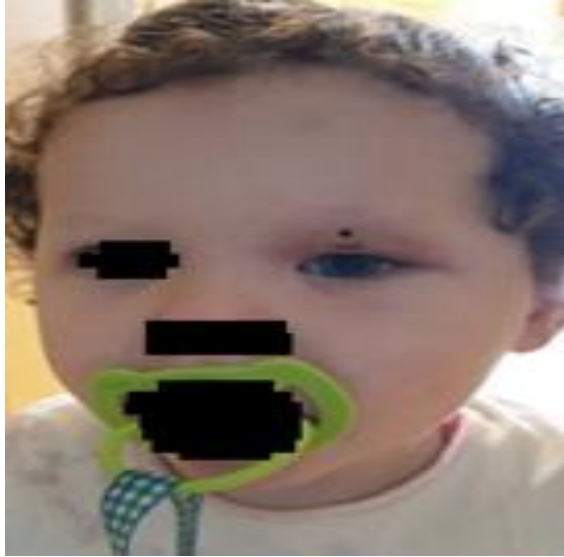

Figure 3: improvement in left eyelid swelling (the eye can easily be opened) 48hours after intravenous treatment, notice the wound scar (*) on the upper eyelid

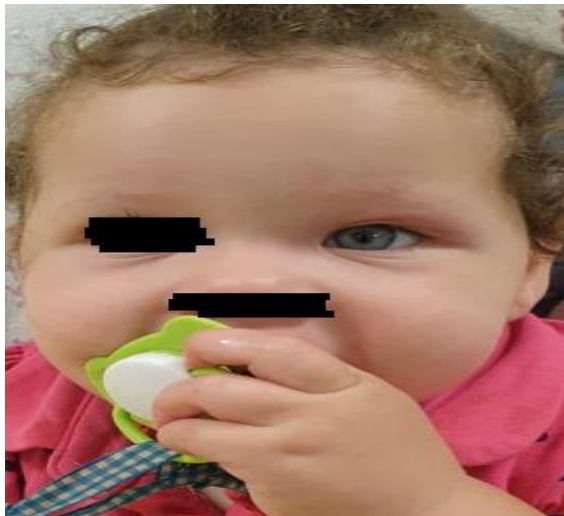

Figure 4: clinical photography on the 10th day of treatment : fully healed

Discussion

Orbital cellulitis is an infection of the soft tissues posterior to the orbital septum. It represents a rare but

severe condition among children, root of many intracranial complications.

90% of cases occur as a secondary extension of acute or chronic bacterial sinusitis, especially the ethmoid sinuses via a thin, possibly dehiscent, lamina papyracea[4]. Other extensions of periorbital structures include the face/eyelids, dacryocystitis and dental infections. Exogenous causes including trauma and orbital/periorbital surgery are rare in infants and a little palpebral wound may be the starting point in babies due to quick and important inflammatory reactions [3-5-8].

Orbital clinical findings include proptosis, ptosis and restriction of ocular motility, ocular pain, and chemosis. If There's a decreased visual acuity, or relative afferent pupillary defect, one must consider compressive optic neuropathy which warrants urgent aggressive management [3].

In our case, the left upper eyelid swelling was massive and we were unable to open the eye or appreciate ocular motility and pupillary reaction. In such cases, orbital CT scan appears as a key exam for diagnosis.

We performed a CT scan of the orbits, the maxillo-facial unit, and the brain in our case and we were able: first, to confirm the diagnosis. Then, to classify the cellulitis and exclude an orbital abscess, which may require a surgical intervention and finally, sinusitis was ruled out as an origin of the cellulitis.

Considering medical history and CT scan images demonstrating no sinusitis, we included the badly managed orbital trauma in the etiopathogenesis of the orbital cellulitis in our case. In fact, the use of non-steroidal anti-inflammatory substances interfered with the immune system and worsened the clinical findings.

The use of non-steroidal anti-inflammatory drugs should be prohibited in such cases[9].

Many classifications are proposed to classify orbital soft tissue's infections as Chandler, Jain and Rubin, and others.

Chandler's classification is a CT scan based classification that distinguishes pre-septal cellulitis (Chandler stage 1), which affects the eyelids and adnexa, without extending beyond the septum, from the more dangerous infections that develop posteriorly to the orbital septum, i.e., orbital cellulitis (OC, Chandler stage 2), sub-periosteal abscess (SPA, the collection of pus in the lamina papyracea, Chandler stage 3), or orbital abscess (OA, Chandler stage 4). Chandler stage 5 refers to cavernous sinus thrombosis[2].

Our infant was classified as Orbital Cellulitis, Chandler stage 2 since no collected abscess was found on CT scan.

In post-traumatic orbital cellulitis, the most common organisms isolated are *Staphylococcus aureus* and *Staphylococcus pyogenes*. Younger children (under

9 years old) are more likely to have a single bacterial isolate, than older children.

Large case series, report that the association of aerobic and anaerobic organisms is reported after a trauma and don't have to be neglected[4,7].

Clinicians should consider routine anaerobic coverage in antibiotic selection, even when the history is not suggestive of anaerobic etiology[8].

Because of the high risk of the infection spreading to the intra-orbital or intracranial compartment at a high speed, hospital admission should be done from early stages with close monitoring.

Medical treatment is preferred in the management of orbital cellulitis in children while surgery is recommended only if there is no improvement or there are worsening clinical findings after 2 to 3 days of medical treatment [2-3-8].

Empiric intravenous antibiotics are chosen to cover both gram positive and gram-negative pathogens. These antibiotics must provide adequate penetration to the central nervous system in order to decrease the risk of intracranial diffusion.

Published antimicrobial recommendations vary, but for orbital cellulitis, we generally include a second or third generation cephalosporin, an aminosid or in areas with high rates of Multi Resistant Staphylococcus Aureus (eg, US) vancomycin. Some authors advocate for additional anaerobic coverage with metronidazole or clindamycin if certain risk factors are present, such as traumatism, dental infections or sinusitis. [2-3-8-9]

In our case, we associated cefotaxime (third generation cephalosporin), amikacin (an aminosid) and metronidazole. The resolution was rapid and therefore the surgery was not needed.

We keep in thought, that an occluded baby's eye for one week may develop a deprivation amblyopia. For that reason, we addressed our baby to a pediatric ophthalmologist for an adapted vision screening in the aim to detect a possible amblyopia.

Conclusion

In this case, we showed the gravity of managing a little palpebral wound with non-steroidal anti-inflammatory drugs without prophylactic antibiotics. Symptom progression may be insidious if supervision is lacking and self-reporting is inadequate.

Clinicians should keep in mind orbital cellulitis as a potential complication of any adjacent infection. Early diagnosis and treatment of pediatric orbital cellulitis is mandatory in order to avoid severe complications.

Patient Consent

Done

Conflicts of interest

Authors do not declare any conflict of interest.

Funding

This research did not receive any external funding

References

1. Wong, S. J., & Levi, J. (2018). Management of pediatric orbital cellulitis: A systematic review. *International Journal of Pediatric Otorhinolaryngology*, 110, 123-129. <https://doi.org/https://doi.org/10.1016/j.ijporl.2018.05.006>
2. Toretta, S., Guastella, C., Marchisio, P., & Bosis, S. (2019). Sinonasal-Related Orbital Infections in Children: A Clinical and Therapeutic Overview. *J. Clin. Med.* <https://doi.org/https://doi.org/10.3390/jcm8010101>
3. Williams, K., & Allen, R. (2019). Paediatric orbital and periorbital infections. *Current Opinion in Ophthalmology*, 30, 349-355. <https://doi.org/10.1097>
4. Saadouli, D., Yahiaoui, S., Ben mansour, K., Masmoudi, M., El Afrit, M., & Samoud, A. (2019). Orbital cellulitis in children: Report of 60 cases. *Journal Français d'Ophthalmologie*, 42, 1056-1061. <https://doi.org/10.1016/j.jfo.2019.06.008>
5. Mukherjee, B., & Priyadarshini, O. (2013). An unusual case of orbital cellulitis. *Eye*, 27, 678-679. <https://doi.org/10.1038>
6. Chew, W., Kwek, J., Anicete, R., & Low, M. Y. (2022). Pediatric orbital cellulitis: Case report of an unusual etiology and pathogen. *Ear, Nose & Throat Journal*. <https://doi.org/https://doi.org/10.1177/01455613211064002>
7. Breigning, S., Roques-Ginetes, M., Marquoux, M., & Bloom, M. (2012). Cellulite néonatale à streptocoque du groupe B. *Archives De pédiatrie*, 19(10), 1079-1081. <https://doi.org/10.1016>
8. Clinical Practice Guidelines : Periorbital and orbital cellulitis [Internet]. [cité 23 juill 2022]. Disponible sur: https://www.rch.org.au/clinicalguide/guideline_index/Periorbital_and_orbital_cellulitis/
9. Gill, P. J., Parkin, P. C., & Begum, N. (2019). Care and outcomes of Canadian children hospitalised with periorbital and orbital cellulitis: protocol for a multicentre, retrospective cohort study. *BMJ Open*, 9(12). <https://doi.org/10.1136/bmjopen-2019-035206>